

**PATIENT**

Elwood Henry

**SPECIES**

Feline

**BREED**

DSH

**SEX**

Male Neutered

**AGE**

13.8 years

**WEIGHT**

18lbs

**INTERPRETED BY**

Maggie Machen Lamy,  
DVM, DACVIM  
(Cardiology)

**IMAGING PERFORMED BY**

Loetitia Saint-Jacques,  
LVT

**HOSPITAL NAME**

VCA Lakeside Animal  
Hospital

**REFERRING VET**

Dr. Wessels

**INVOICE**

47161

**DATE**

3/9/26

**PRESENTING CLINICAL SIGNS**

History: Chronic bronchitis suspected secondary to feline asthma first diagnosed in December 2024. Beginning 02/22/26, started coughing and wheezing excessively even when being given Flovent and Albuterol inhaler. On physical exam on 2/24/26, had harsh lung sounds bilaterally, but was unable to auscultate heart murmur at that time. No arrhythmias auscultated. Eating/drinking normally. No v/d/s. Very obese; BCS 8/9. On Flovent Inhaler 110ug - 1 puff q12h Albuterol inhaler 90ug - 1 puff PRN Furosemide 12.5mg - 1.5 tablets PO q24h.  
-Abnormal PE/Chem/CBC/UA Results: CBC/Chem/UA performed 01/13/26: BUN- 34 CREA- 1.6 USG- 1.015 Mild lymphopenia - 702 Mild monocytosis - 702

**ELECTROCARDIOGRAPHIC FINDINGS**

A six lead ECG is available at 25mm/s; 10mm/mV. The average heart rate is 180bpm. The rhythm is sinus in origin, with a p for every QRS complex and vice versa. The P wave morphology is positive with a normal dimension. Normal PR. The QRS morphology is inverted. The MEA is shifted left. No ectopic beats, pauses or dysrhythmias observed.  
ECG diagnosis: Normal sinus rhythm. Left axis deviation.

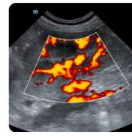
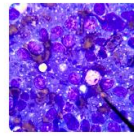
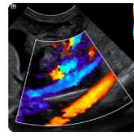
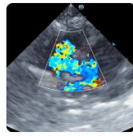
**ECHOCARDIOGRAM FINDINGS**

2D, m-mode, color flow and doppler imaging is available. The left ventricular wall is mildly increased in dimension. There is a mildly hyperechoic endocardium consistent with fibrosis. Mild symmetric papillary muscle hypertrophy and remodeling. The right ventricle is subjectively normal in size and morphology. There is mild left atrial enlargement present. No right atrial enlargement present. Normal RVOT velocity. Trace TR. Normal LVOT velocity. There is no obvious systolic anterior motion (SAM) of the mitral valve present. No MR. No significant AI or PI. There is no pericardial effusion noted. No pleural effusion appreciated. No obvious cardiac tumors.

**CARDIAC CHART**

FELINE CARDIAC PARAMETERS	BODY WEIGHT (kg)	HR (BPM)	IVSd (cm) (Moise, Pipers)	LVIDd (cm) (Moise, Pipers)	LVWd (cm) (Moise, Pipers)	FS (%)	EF (%)
NORMAL PARAMETER	-----	150-240	0.35-0.55	<2 (mean 1.5)	3.5-0.55	35-67	80-100
PATIENT	8.2	200	0.71	1.5	0.62	47	90
FELINE CARDIAC PARAMETERS	LA/AO (Boon)	LA/AO HEART BASE (Swe) (Abbott)	LA 2D short axis Base view (cm) (Abbott)	LVOT VEL (m/s)	RVOT VEL (m/s)	E max (m/s)	
NORMAL	<1.5	<1.3	<1.2	<1.6	<1.3	<0.9	
PATIENT	NM	1.2	1.5	1.5	1.2	NM	

*\*Note: All measurements based upon multi-modal images and methods. An average value is reported.*  
Adapted from June Boon, Veterinary Echocardiography, 1998  
Abbott J & MacLean H JVIM 2006;20: 111-119, Moise et al. Am J Vet Res 47:1476, 1986. Pipers et al. Am J Vet Res 40:882, 1979.



**PATIENT**

Elwood Henry

**SPECIES**

Feline

**BREED**

DSH

**SEX**

Male Neutered

**AGE**

13.8 years

**WEIGHT**

18lbs

**INTERPRETED BY**

Maggie Machen Lamy,  
DVM, DACVIM  
(Cardiology)

**IMAGING  
PERFORMED BY**

Loetitia Saint-Jacques,  
LVT

**HOSPITAL NAME**

VCA Lakeside Animal  
Hospital

**REFERRING VET**

Dr. Wessels

**INVOICE**

47161

**DATE**

3/9/26

**INTERPRETATION OF THE FINDINGS & FURTHER RECOMMENDATIONS**

Hypertrophic cardiomyopathy (HCM) is a rule out diagnosis once a patient is deemed normotensive and euthyroid. Both should be ruled out in this case as contributing factors. The degree of disease is mild, with only mild LVH and slight LA dilation. This would indicate the risk for clinical issues is low at this time. Flow through the great vessels is normal, and no significant valve regurgitation is seen. No additional pathology is identified. The ECG is largely unremarkable with a normal sinus rhythm. A left axis deviation is a benign conduction abnormality common in older cats.

Even with mild disease seen here, in the absence of CHF these findings are unrelated to reported respiratory signs. Lasix can be safely discontinued.

No medications are typically indicated prior to significant atrial dilation, as many cats will experience naturally slow progression. It is important to note that no medications have been shown to definitively alter long term outcome at this stage, particularly in the absence of SAM. *Regarding the newly available drug Felycin-CA1:* Recent data reports that Felycin-CA1 may improve the degree of LV hypertrophy in some cats with naturally occurring subclinical HCM. The clinical benefit is currently unknown and is still being investigated. The HALT trial is actively enrolling HCM cats all over the US in order to acquire prospective data on a larger sample size of cats. Should you wish to use the medication, the published dose is 0.3mg/kg weekly, and the drug should be avoided in cats with advanced cardiac changes, diabetes, non-healing wounds, active infections or liver disease. The medication is an immunosuppressant and should be used with caution. For further information, please visit [www.triviumvet.com](http://www.triviumvet.com).

Long term prognosis is guarded for subclinical HCM, with a great deal of variability in rate of progression. The REVEAL study showed that approximately 7% of asymptomatic cats with HCM will develop CHF or a cardiogenic thrombus within 1 year, 20% within 5 years, and ~30% within 10 years. Close monitoring for progressive LA dilation going forward will help better predict long term outcome.

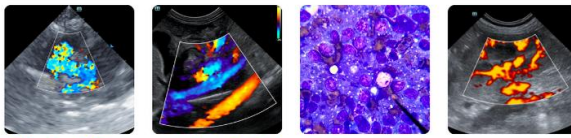
Monitor at home for any respiratory issues or signs of blood clot events (neurologic change, paralysis, etc.).

Anesthetic risk is considered mildly elevated; however, judicious fluid administration is advised if needed with careful monitoring to screen for fluid overload. A reasonable protocol includes opioid/benzodiazepine premedication, propofol induction, isoflurane maintenance. Avoid ketamine, telazol, acepromazine and Dexdomitor. Additionally, drugs that stimulate heart rate should be avoided unless clinically necessary (glycopyrrolate, atropine).

Risk for complication with steroid or fluid use typically follows LA dilation, which in this case is mildly elevated. If needed, monitoring of RR/RE is advised particularly in the initiation phase.

**PLAN**

A screening blood pressure and T4 are recommended every 6 months lifelong.



**PATIENT**

Elwood Henry

**SPECIES**

Feline

**BREED**

DSH

**SEX**

Male Neutered

**AGE**

13.8 years

**WEIGHT**

18lbs

**INTERPRETED BY**

Maggie Machen Lamy,  
DVM, DACVIM  
(Cardiology)

**IMAGING  
PERFORMED BY**

Loetitia Saint-Jacques,  
LVT

**HOSPITAL NAME**

VCA Lakeside Animal  
Hospital

**REFERRING VET**

Dr. Wessels

**INVOICE**

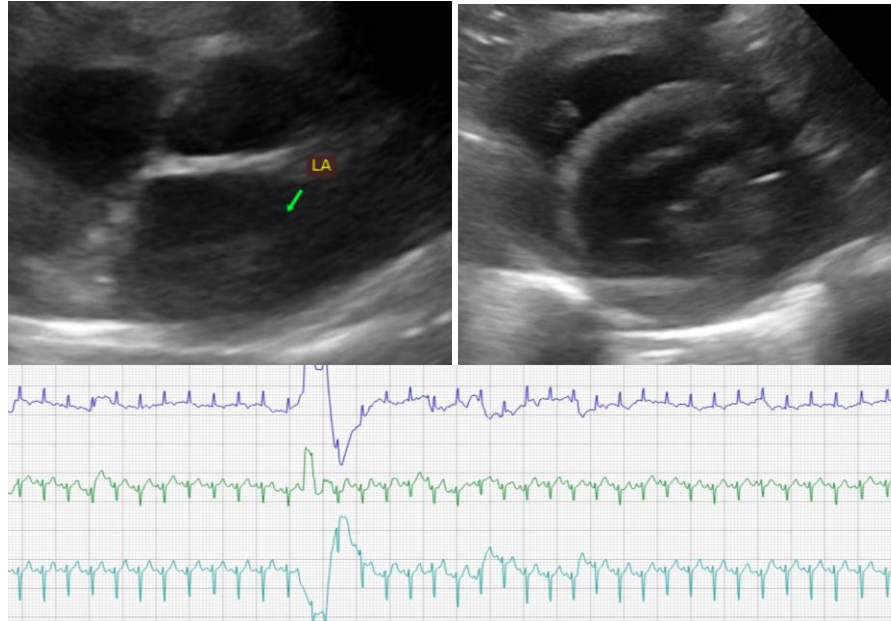
47161

**DATE**

3/9/26

A recheck echocardiogram is recommended in 6 months to assess for progression, sooner if any issues arise in the interim.

**IMAGES**



**The information and recommendations provided are based on the images presented by the referring veterinarian. No evaluation can be communicated regarding pathology that was not visible in the image/video clips provided.**

Thank you for this referral. This report was generated using transcription software, and minor dictation errors may be present. If the clinical or image interpretation does not parallel your findings or if I can be of any further assistance, please contact me.

**Maggie Machen Lamy, DVM**  
**Diplomate of the American College of Veterinary Internal Medicine (Cardiology)**  
info@sonopath.com